

# Shaken baby syndrome: theoretical and evidential controversies

RA Minns

Consultant Paediatric Neurologist, Royal Hospital for Sick Children and Child Life and Health, University of Edinburgh, Edinburgh, Scotland

**ABSTRACT** Recent controversies have focused on whether shaking can injure the infant brain and if a diagnosis of SBS can be confidently made and distinguished from accidents (short falls) and non-traumatic conditions.

This article reviews documented cases, animal, biomechanical, and computer-modelling evidence to support the contention that shaking alone without additional impact results in a rotational brain injury with tearing of cortical emissary veins, parenchymal shearing, cervico-medullary, and hypoxic-ischaemic injury.

While the terminology SBS is best avoided because it implies a mechanism in what is usually an unwitnessed injury, a more secure diagnosis of NAHI can be offered, with varying degrees of certainty, based on clinical, imaging, and ophthalmological findings after excluding conditions simulating these features.

The type of brain injury (inertial, contact, hypoxic-ischaemic) and the context in which it is sustained, may enable an opinion about whether the mechanism is consistent with either a purely rotational or rotational impact-deceleration injury, compressive, penetrative or other combined mechanism.

**KEYWORDS** Diagnosis, differential diagnosis, evidence, non accidental head injury, outcome, shaken baby syndrome

**LIST OF ABBREVIATIONS** cerebrospinal fluid (CSF), computerised tomography (CT), magnetic resonance imaging (MRI), non accidental head injury (NAHI), sub-arachnoid hemorrhage (SAH), shaken baby syndrome (SBS), shaken impact syndrome (SIS), subdural haematoma (SDH)

**DECLARATION OF INTERESTS** No conflict of interests declared.

## HISTORICAL BACKGROUND

The first description of multiple fractures in the long bones of infants associated with chronic SDH was by Caffey in 1946<sup>1</sup> who described six infants with chronic SDHs, and where a history of injury to the long bones and of the head was lacking. There were no radiological or clinical conditions predisposing to pathological fractures. In two of the six cases, retinal haemorrhages are mentioned and he recommended that the presence of unexplained fractures in the long bones warranted investigation for SDH.

In the late 1960s, Ommaya *et al.*<sup>2,3</sup> in his research of the biomechanics of central nervous system trauma, reported that high-speed rotational displacements of the head on the neck, without significant direct head impact, could produce cerebral concussion and haemorrhages over the surface of the brain and spinal cord of sub-human primates. Ommaya and Yarnell went on to describe the case histories of two patients with SDH

caused by whiplash injury alone.<sup>4</sup> They derived the approximate level of rotational acceleration and indicated a value of 1,636 radians per sec<sup>2</sup>, and hypothesised that the crucial factor was the inertial effect of the easily deformable brain, moving with a time lag, after rotatory displacement of the skull. Attachments between the outer surface of the brain and the inner surface of the skull are subjected to powerful tensile and shearing stresses. The cortical veins, particularly where they enter the more fixed portions of the dural sinuses, can tear under such conditions and result in SDHs. The level for SDH was thought to be close to the threshold for cerebral concussion.

In 1971, Norman Guthkelch,<sup>5</sup> a consultant neurosurgeon working in Hull, England, reported details of two infants with SDHs, without external marks of injury on the head. Extrapolating from the previous animal work of Ommaya,<sup>2,4</sup> Guthkelch suggested that in some cases repeated acceleration/deceleration rather than direct violence was the cause of the haemorrhage, i.e. the

Published online September 2004  
(abbreviated version)

Correspondence to RA Minns,  
Consultant Paediatric Neurologist,  
Royal Hospital for Sick Children and  
Child Life and Health, University of  
Edinburgh 20 Sylvan Place,  
Edinburgh, EH9 1UW

tel. +44 (0)131 536 0637

fax. +44 (0)131 536 0821

e-mail Robert.Minns@ed.ac.uk

infant having been shaken rather than struck. He also noted that they were often bilateral, and conjectured that shaking might explain the high frequency of SDH in 'battered children' compared to its incidence in head injuries of other origins. All cases of infantile SDH were then assumed to be traumatic unless proved otherwise, and he felt it unwise to disregard the possibility that they had been caused by serious violence simply on the basis that there were no gross fractures in the limbs or spine. Guthkelch was therefore the first to suggest that babies have been injured by shaking, causing SDH.

In a seminal article in 1972, Caffey<sup>6</sup> described 27 infants thought to have been shaken and sustained SDHs and metaphyseal avulsions. The metaphyseal avulsions took the form of small fragments of cortical bone torn off the external edge of the cortical wall at the metaphyseal level, where the periosteum is most tightly bound to the cortex. He postulated that these were due to indirect traction, stretching, and shearing acceleration/deceleration stresses on the periosteum and articular capsules, rather than a direct impact stress such as a smashing blow on the bone itself. He similarly considered the SDHs that occurred in 85% of the infants, and were frequently associated with bilateral retinal haemorrhages. These were not usually caused by direct impact injury but by indirect acceleration/deceleration traction stresses such as whiplash shaking of the head.

The term 'whiplash shaken baby syndrome' is attributed to Caffey who used it to explain the constellation of infantile subdural and subarachnoid haemorrhage, traction-type metaphyseal fractures and retinal haemorrhages, and was based on the earlier evidence that angular (rotational) deceleration is associated with cerebral concussion and SDH. Caffey also expressed concern that many cases of cerebral palsy, developmental delay, and epilepsy seen in young children might be attributable to this type of injury. The basic definition of whiplash shaken infant syndrome or SBS has not essentially changed since then.

In the Children's Hospital in Philadelphia, USA, Duhaime<sup>7</sup> reported a case series of 48 children most of whom had retinal haemorrhages, subdural or subarachnoid haemorrhages, and a history suggestive of abuse. There were no clinical signs of blunt trauma in 25% of these cases, but of the 13 children who died, all had evidence of blunt trauma on pathological examination including seven without clinical findings of blunt trauma. Duhaime and her team developed doll models and measured acceleration forces while the dolls were being shaken or shaken with impact. These measurements were then adapted to data from injuries generated by shaking non-human primates, and they concluded that shaking alone did not generate sufficient force to cause the type of injuries seen in SBS, and concluded that impact must be an accompaniment

and suggested an alternative 'shaken-impact syndrome'.

Since the original description, numerous case series of shaken infants have been reported from most parts of the world. For example 364 cases, over a 10-year period, were reported to Child Protection Teams in 11 paediatric tertiary care hospitals in Canada<sup>8</sup> and these large numbers, including recent high profile cases, have generated controversies which have resulted in confusion in the law courts and in the public perception of this form of child abuse. These controversies specifically stimulate the following questions:

- Can shaking injure the infant brain and what degree of shaking would be necessary?
- Can the diagnosis of SBS be made and, if so, with what degree of certainty?
- Can accidental injuries or other non-traumatic conditions simulate this syndrome?

### CAN SHAKING INJURE THE INFANT BRAIN AND WHAT DEGREE OF SHAKING WOULD BE NECESSARY?

The literature in support of SBS consists largely of clinical observations beginning with Guthkelch and Caffey who collated many previously reported cases of bilateral SDH, intraocular bleedings, and multiple traction changes in the long bones where there was no evidence of external head trauma; and/or strong testimony suggesting injuries could only have been the product of shaking. Across the literature the average percentage of cases thought to be due to shaking only is estimated at approximately 33% from those reports where a clear distinction is made between shaking and shaking with impact. Such collected data, which shows that almost one-third of non-accidental SDHs have no evidence of impact is, in itself, strong evidence in favour of the syndrome.

#### *Perpetrator acknowledged/confessed cases*

From a database of 124 cases in Scotland,<sup>9</sup> in 23% an adult was known to have acknowledged or confessed to injuring the child and 89% of these infants had SDHs, 68% retinal haemorrhages, 36% skeletal injuries, and 21% bruising. Fourteen per cent had a skull fracture. The 'confessed' cases were not delineated into those with shaking with impact or shaking alone. However, the relatively small proportion with skull and skeletal fractures, bruising, and external injuries are consistent with a large proportion being due to shaking alone. The reliability of confessions or acknowledgement by perpetrators of any sort of injury can be questioned and there are several reasons why the accused may admit to an unwitnessed episode of injury, but there is no reason to believe that any of the above cases were anything but uncoerced confessions.

### A single carefully documented case

Even a single, carefully documented case of shaking alone is sufficient to establish the possibility that shaking alone can result in head injury. One such case concerned a four-month-old child who was admitted via the A&E department, unresponsive and with laboured breathing. There was evidence of raised intracranial pressure including a bulging fontanelle, intermittent bradycardia, extensor posturing, and eye deviation. Widespread bilateral retinal haemorrhages extending to the ora serrata and involving all retinal layers and the macular were confirmed by an ophthalmologist. Petechial skin haemorrhages were noted at the right palpebral fissure and upper thorax. A right SDH surrounded the cerebral hemisphere, and extended to the other hemisphere and subtemporal regions, with some brain swelling but no focal intracerebral lesion. This presentation with an acute encephalopathy, bilateral retinal haemorrhage, and SDH was followed, shortly after the child's admission to hospital, by an acknowledgement of the perpetrator, that the child was shaken angrily 'in the air' (without impacting on any hard or soft surface) for between five and ten seconds as a response to protracted crying and failure to pacify while solely in the care of the adult perpetrator. The infant became immediately limp, had difficulty breathing, and the ambulance was summoned. From this single case it is clear that adults can and do shake infants and this does cause brain damage in the form of an encephalopathy with subdural and retinal haemorrhages, and that impaction on any type of surface is not necessarily required.

### Physiological factors predisposing the infant to shaking injury

While injury from shaking is possible in older age groups there are a number of factors that particularly predispose the infant to injury from shaking, such as

- the relatively large and heavy head in relationship to the body size (the brain represents 10% of the infant weight and only 2% of the adult weight);
- the neck muscles are weak and there is little head control so that even in picking up the infant a hand is required behind the occiput to prevent the head flopping back. The force required therefore only needs to be sufficient to overcome the neck muscles and allow the head to whiplash with each shake. Strong neck muscles prevent a boxer being easily knocked out, or a footballer every time he 'heads' the ball, and wearing a collar prevents experimental knock-outs and damage in non-human primates;
- the extracerebral space is relatively large in the normal infant as seen on routine ultrasound and CT scans in the first year of life and can be up to 1 cm in depth and is maximal at about 5 months of age. This hydrostatic cushion allows skull growth to keep pace

with brain growth, i.e. a physiological craniocerebral disproportion. Whether this additional space predisposes to easier rupture of bridging veins and risks subdural bleeding with lesser degrees of rotational injury is not certain;<sup>10</sup>

- there is a physiological laxity of the meninges (falx and tentorium) in infancy compared to older children and taken in conjunction with the greater extracerebral space means that there is relatively more space and less tethering of the brain allowing more movement within the infant's skull; and
- a higher water content of the infant brain with an absence of myelination in the white matter and a full complement of neuronal cell bodies in the grey matter means an increased difference in the specific gravity between grey and white matter of the infant compared to the adult brain. That is, for a given force, there will be a greater difference between inertia and tangential accelerations at different radial positions of the grey matter compared to the white, and this difference will predispose to shearing.

Although the above predispose to shaking injury in infants (mostly between two and five months of age), it has been described rarely in adults ('shaken adult syndrome') where extreme violence by shaking has been the predominant mechanism of injuring. Pounder<sup>11</sup> described a 30-year-old Palestinian prisoner who died with SDH, retinal haemorrhage, diffuse axonal injury, and bruising over the chest and shoulder from fierce shaking on at least 12 occasions during interrogation over a 3-day period. Carrigan *et al.*<sup>12</sup> similarly reported domestic violence in the form of shaking to a 34-year-old female, who presented with retinal haemorrhages, SDHs and patterned bruising.

### Experimental animal models

Ommaya *et al.*, described an experimental whiplash injury study on 50 Rhesus monkeys that demonstrated cerebral concussion, gross haemorrhages, and surface contusions of the brain and upper cord, produced by rotational displacement of the head on neck alone, without any significant direct impact.<sup>2</sup>

A further biomechanical study by Gennarelli and Thibault proved that impact was not necessary to cause acute SDH in primates.<sup>13</sup> In their study the heads of Rhesus monkeys were securely fitted into a helmet that was attached to a pneumatic actuator and linkage system. The system was programmed to deliver a single acceleration/deceleration pulse to the head by rotating it through a 60° arc in times varying from 5–25 msec with magnitudes between 100–3,000G. Angular acceleration produced acute SDH of such a magnitude to cause the animal's death in 37 of 128 cases. The SDHs were usually bilateral overlying ruptured parasagittal bridging veins. The acceleration magnitudes and frequencies were probably

greater than could be induced manually by an adult shaking an infant. Choosing the deceleration phase may have overestimated the tolerances for SDH because the majority of bridging veins have been shown to drain forwards from the brain into the sagittal sinus and would therefore be stretched more during forward acceleration than deceleration which would likely cause compression before tension.

Shaking produces an oscillatory motion due to repeated applications of the impulse in a periodic fashion at a frequency of 4–10 Hz.<sup>7</sup> It may be that it is necessary to shake a critical frequency similar to the natural resonant frequency of the head on neck to produce the maximum intracranial effects. Additional studies are needed to define the natural resonant frequency in children, but Ommaya<sup>14,15</sup> identified the natural frequency of skull and intracranial contents as 5–10 Hz in sub-human primates and proposed that the natural frequency in the adult human would scale to be 4–5 Hz.

Mechanical properties of adult brain tissue have been measured *in vitro* under various conditions and both mature and immature porcine brain tissue was tested in a variety of orientations over a broad strain range, and has shown that brain tissue is non-linear and viscoelastic with properties varying across the strain magnitude and rate.<sup>16,17</sup> Paediatric tissue, however, was reported to be less stiff than adult tissue at the smallest strain tested but over the rest of the testing range paediatric porcine brain tissue was significantly stiffer than adult tissue. There is also some evidence that immature axons, not yet fully myelinated, may be more susceptible to deformation than adult axons.<sup>18</sup> Paediatric brain tissue may therefore have a lower injury threshold than adult brain tissue.

### Computer modelling

Computer or finite element modelling involves representing a solid model as a mass of a finite number of discrete elements, for which the governing equations of mass, momentum and energy can be built into a matrix.

Zhou *et al.*<sup>19</sup> developed a 3-dimensional model of a fiftieth percentile male human head consisting of scalp, skull, dura, falx, tentorium, pia, CSF, venous sinuses, ventricles, grey and white matter of the cerebrum and cerebellum, brain stem, and bridging veins. The model was loaded with an impulsive angular acceleration in both the sagittal and lateral planes, scaled from the monkey experiments of Abel *et al.*,<sup>20</sup> and deduced peak angular accelerations of 7,030 rads per sec<sup>2</sup> occurring at 4ms and peak angular decelerations of 9,192 rads per sec<sup>2</sup> occurring at 32ms. Their bridging vein elements experienced stretch ratios of 1.383 during sagittal rotation.

The first 3-dimensional model of SBS that included an accurate representation of the CSF, was developed by

Morison.<sup>21</sup> This new model resulted in several important conclusions. First, it has shown that the combined effect of buoyancy and acceleration reaction forces it to reduce the relative translational acceleration of the brain within the skull to only 0.22% of the translational acceleration applied to the skull. This explains why impacts and inertial accelerations that produce mainly translational head accelerations are unlikely to cause severe brain injury. There is ample literature with clinical observations supporting the notion that straight-line head-impacts with fast moving rigid bodies cause severe skull fractures but no concussion. Second, the rotational component of the shaking motion is responsible for approximately 93% of the bridging vein strain, and the tentorium cerebelli which probably provides the brain with most of its protection against sagittal rotation is still less effective than the CSF at providing protection against translation. Rotational accelerations are therefore extremely dangerous to humans and this has been well acknowledged since Holbourne,<sup>22</sup> the primate experiments of Ommaya and Generelli,<sup>3</sup> and the observations of woodpeckers by May *et al.*<sup>23</sup> This current model gives support to the hypothesis of Hodgson *et al.*<sup>14</sup> that the CSF protects against translational acceleration perfectly but effectively acts as a lubricant to brain rotation.

Maximum bridging vein strain is experienced as the skull is at the rear extremity of its motion and accelerating forwards. At this point in the motion the higher density brain rotates backwards relative to the skull (which is starting to rotate forwards), stretching the bridging veins which drain forwards from the brain surface to the mid-sagittal sinus. This is consistent with the observation that the brain is more susceptible to injury from occipital rather than frontal impacts.

Finally, this model has shown that the maximum bridging vein stretch ratio is very sensitive to shaking frequency, especially at frequencies between 2–5 Hz. A relatively small increase in shaking frequency will result in a disproportionate increase in bridging vein stretch ratio and the likelihood of rupture with SDH. The average ultimate stretch ratio of bridging veins was previously found to be 1.5, although some veins may fail at ratios of as little as 1.15. These results show that shaking at a frequency of 4 Hz and an amplitude of  $\pm 60^\circ$  can produce a stretch ratio of approximately 1.26 and therefore this model shows that SDH may well be a possible result of manually shaking a baby.

### Biomechanical models

It is difficult to apply an adult paradigm to children's inflicted head injury because fundamental work was undertaken on adult animals and there is little information on the immature animal subjected to different types of injury. Inflicted injury is particularly difficult to simulate because the magnitude of the acceleration, the duration,

the direction, and presence of impact or not, are not known and hence cannot be factored into an experimental situation. The consensus for adult primary traumatic brain injury is that focal injuries may be contact injuries (soft tissue injury, skull fracture, focal SDH, epidural haemorrhage, superficial cortical contusion, and laceration) or translational inertial injuries (contrecoup, intracerebral haematoma, SDH, SAH, and petechial haemorrhages). Diffuse injuries (rotational inertia) are associated with:

- concussion (mid-brain shear), tearing of surface bridging veins resulting in SDH and SAH,
- interhemispheric SDH,
- frontal-temporal rotational sphenoid impact,
- gliding contusions/lacerations at grey-white interface,
- traumatic axonal injury,
- corpus callosum and cerebellar peduncle white matter tearing,
- cranio-cervical junction injury, and
- diffuse retinal haemorrhages/retinoschisis.

Secondary injuries are ultimately hypoxic/ischaemic/reperfusion injuries, predominantly from cerebral oedema, fits, reduced cerebral perfusion pressure, increased intra cranial pressure causing infarction and herniation syndromes, hypotension, hypoxia, and pyrexia.<sup>24</sup>

In biomechanical studies on the 'shaken' doll models of infants that were constructed by Duhaime<sup>7</sup> in which rotational accelerations and velocities experienced by the head during vigorous shaking were compared with those during impact against various surfaces. They established that impact produced peak accelerations up to 50 times that produced by shaking alone. They predicted (after scaled comparison) that there would be no injuries for shaking alone, but there would be injury for all impacts even against a padded surface. They deduced that while there may be no visible soft tissue injury with impact against a soft surface, there can be dramatic pathological loads experienced by the brain. Their injury thresholds for concussion, SDH, and diffuse axonal injury were derived from studies in adult primates and where the rotational motion was from a single inertial event.

In Edinburgh, the maximum angular acceleration and linear acceleration produced on the head of a doll model during repetitive shaking by healthy adult volunteers was investigated.<sup>25</sup> This doll model was constructed by the Medical Physics department with dimensions similar to an average two-month-old infant. The study demonstrated that the maximum values obtained after a number of 'shakes' for angular acceleration was 326–890 rads per sec<sup>2</sup> and the average value was 300 rads per sec<sup>2</sup> respectively. The maximum and average values for the resultant accelerations were 4–15g and 3.5g respectively for males. Comparison of our acceleration values showed

that our peak values for angular acceleration were less than the mean values of those obtained by Duhaime.<sup>7</sup> This may be explained by different 'doll neck designs'. Linear accelerations were comparable between the two studies. A further doll model study from de San Lazaro *et al.*<sup>26</sup> has recorded peak acceleration values of 3g for 'normal' shaking and approximately 7g for 'violent' shaking. Although not strictly comparable because of the different mannequin designs (particularly because of the difficulties simulating an infant neck) the results from these three studies would suggest that scaling from adult primate data is not the most appropriate way to argue that shaking alone cannot be responsible for the infant's brain injuries.

Results from the Edinburgh study have defined the upper limits (maximum shaking ability) of the biomechanics of the shaker in terms of duration, frequency, and accelerations (in adult volunteers shaking doll models). Since children are occasionally the target of accusations, children aged 3–15 years who shook 'dead weights' were also included. A significant difference in the duration, mean frequency and mean angle for the different weights shaken, but no differences for the mean accelerations in both adults and children were found, although some younger children could not lift or shake the heavier weights. Children and adults shake the smaller weights and dolls with a frequency that appears to be relatively independent of the weight.

Adults can maximally shake a doll with dimensions equivalent to a 2-month-old infant for a median of 24 seconds at an average frequency of 3.5 Hz, reaching an average maximum linear acceleration of 4,200 cm sec<sup>-2</sup> at an average angle of 35°. Children, however, shake a dead weight, equivalent to a 2-month-old infant, for a median of 20 seconds at 2 Hz, with an average maximum acceleration of 3,100 cm sec<sup>-2</sup> and an average angle of 39°. From this it is clear that it is not possible to shake for protracted periods with such weights without exhaustion intervening.

### Neuro-imaging studies

There are several studies reporting CT, ultrasound, and MRI appearances of brain injury in children who have suffered inflicted brain injury.<sup>27–31</sup> These papers include cases with and without cranial impact injuries. Barlow *et al.*<sup>32</sup> reported the acute MRI appearances in 12 infants at a mean age of 5.7 months, who had suffered an NAHI and in seven of the surviving children there was no clinical evidence of impact. The MRI findings therefore reflect cases with and without impact, although none had skull fractures or extradural haemorrhages. By contrast, in the children without evidence of impact, 100% (seven out of seven) had SDHs which included subtemporal, suboccipital, and interhemispheric haemorrhage in 71%, 14%, and 57% respectively. Tearing of the surface veins

(Figure 1a and 1b) was evident in 29% and cerebral contusions, lacerations, oedema, asphyxial changes, and petechiae at the grey-white matter junction were also evident. Although a shaking mechanism was not admitted in these cases, they were considered to be NAHI without clinical evidence of head contact.

### Summary

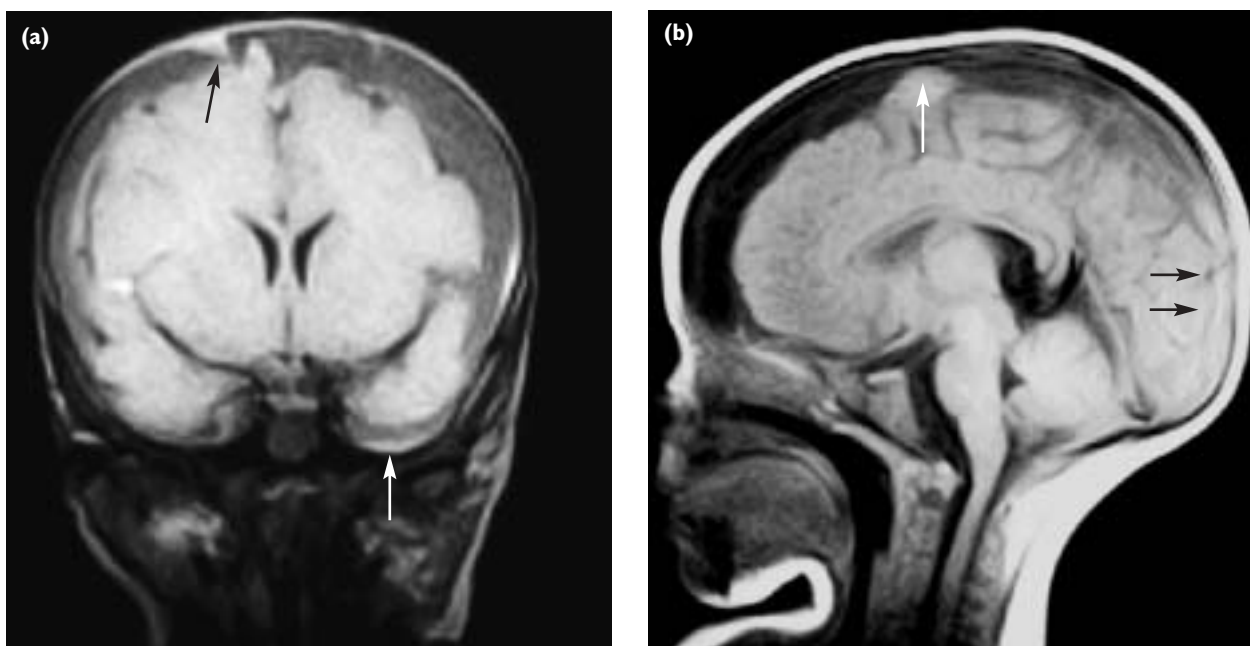
- There is evidence from carefully documented individual and published case series and databases in which the perpetrator has admitted or acknowledged a shaking mechanism that has led to a significant intracranial injury;
- there is evidence of rare cases of adults who have sustained similar types of brain and retinal injuries after excessive shaking;
- there is evidence of experimental animal, biomechanical, and computer modelling research that supports the 'shaking alone' mechanism; neuro-imaging reports of brain damage in areas predicted by biomechanical studies from cases where shaking has been the admitted or has been the suspected mechanism;
- the severe and early brain atrophy<sup>33</sup> which follows the acute injury (Figure 2a and 2b), unlike sequelae of accidental head trauma; and
- although this is almost always an unwitnessed injury and is mostly denied by the perpetrator there are rare cases which have been observed on 'nanny-cams' or close circuit television.

This cumulative evidence is strongly supportive of the contention that adults do shake young infants, and that shaking alone may produce extensive brain injury.

### CAN WE DIAGNOSE SBS?

Although shaking may cause an acute encephalopathy, SDH, and retinal haemorrhages, diagnosing 'shaking' as a mechanism of injury, or attributing any mechanisms of injury, to a particular child who presents with these clinical findings is not possible, because these are unwitnessed injuries that may be incurred by a whole variety of mechanisms solely or in combination. The brain may be injured by impact acceleration, impact deceleration, compression, penetration, rotational injury, or rotation with impact. The 'Principle of the Transposed Conditional'<sup>34</sup> does not allow a 'diagnosis' of the mechanism, but a more generic diagnosis such as NAHI or inflicted head injury should be used in preference to SBS which implies a specific mechanism of injuring.

Lazoritz *et al.*<sup>35</sup> noticed that Caffey's original definition of 'whiplash shaken infant syndrome', and today's SBS or SIS are now commonly used in cases which clearly involve impacts, and even in some cases of impact without shaking. Paediatricians were therefore not implying a mechanism and although they labelled cases SBS what they really intended was NAHI. To be precise for legal purposes, SBS should probably not be used unless there is an unequivocal admission by the perpetrator that shaking alone was the sole mechanism of injury.



**FIGURE 1** (a) FLAIR coronal and (b) T1 sagittal MRI scans on the day of presentation of a 6-week-old infant who presented with fitting, and a spiral fracture of the tibia. Widened subdural spaces are seen with high intensity in the subtemporal region bilaterally. There is a linear high intensity in the right parafalcine region suggestive of clot around a bridging vein. The sagittal image (b) shows widened subdural spaces with a layering of high intensity posteriorly and a focal area over the frontoparietal convexity indicative of a focal clot.

The diagnosis of NAHI is made by the history, a syndromic combination of clinical, radiological, and ophthalmological features and supportive social pathology.

Contributing elements from the history include a changing story of circumstances surrounding the injury, i.e. inconsistency or frequently no explanation offered. The history is often inadequate to explain the very severe clinical presentation of the child and there may additionally be a delay in seeking medical assistance.

The salient features are SDHs, retinal haemorrhages, encephalopathy, rib and metaphyseal fractures, bruising, epileptic seizures, and sometimes features of malicious intent, including cuts, cigarette burns, laceration, scalds, bruising of different ages, and multiple fractures of different ages. The patterns of presentation have been delineated from a database documenting Scottish cases and are predominantly four types.<sup>36</sup>

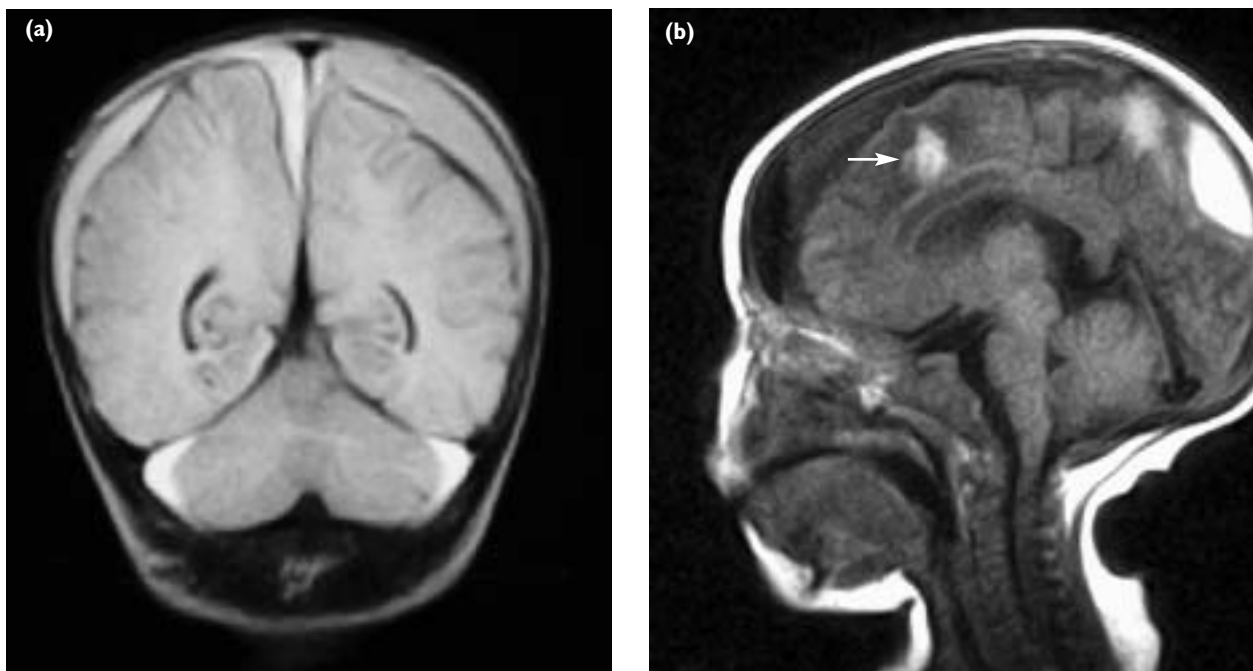
First, the hyperacute encephalopathic presentation or cervico-medullary syndrome which accounts for about 6% of all cases and probably is the result of extreme whiplashing forces where the infant sustains acute injury to the brain stem with localised axonal damage at the cranio-cervical junction, in the cortico-spinal tracts, and in the cervical cord roots, consistent with a hyperflexion-hyperextension injury. Such severe cases are usually fatal, the child presenting with acute respiratory failure from direct medullary trauma and with cerebral oedema evidenced by the 'big black brain' on imaging. Geddes et

al.<sup>37</sup> in a careful necropsy study reported severe brain swelling and hypoxic injury in the brains of these young infants with little axonal shearing and thin layer SDHs. Possible traumatic vertebral artery thrombosis may be a rare mechanism of these fatal injuries from severe rotation.

Second, an acute encephalopathic presentation with a depressed conscious state, raised intracranial pressure, fits, apnoea, hypotonia or decerebration, anaemia, shock, bilateral SDHs, and extensive haemorrhagic retinopathy. There may also be rib and metaphyseal fractures. This was the type of presentation usually referred to by paediatricians as the 'SBS', from repetitive rotational injury. There may also be evidence of impact (as described above), and this was then referred to as the 'SIS'. This is the most common presentation and is seen in some 53% cases.

Third, the presentation may be with a less acute brain injury (non-encephalopathic subacute presentation) without intraparenchymal cerebral hypodensities and without clinical features of a traumatic encephalopathy. These children do however, have SDHs, retinal haemorrhages, rib and skeletal fractures, and bruising in various combinations.

Fourth, a chronic extracerebral presentation is seen in approximately 20% of children who present with a rapidly expanding head circumference, irritability, vomiting, failing to thrive, hypotonia, signs of raised intracranial pressure, and possibly fitting from an isolated, frequently chronic,



**FIGURE 2** (a) FLAIR coronal and (b) T1 sagittal images from the same infant on day 6 and 2 weeks after presentation respectively. The FLAIR image shows a widened subarachnoid space containing clear CSF indicating atrophy. There is also variability in the intensity from the left and right subdural space. The sagittal image (b) shows a persisting high intensity posterior haemorrhage and a more prominent white matter tear is now evident (arrow).

SDH. The presumption here is that if retinal haemorrhages were originally present when the injury happened, they would have disappeared by the time of presentation. Although the child is not encephalopathic at presentation, there is still the potential for later secondary brain insult from raised intracranial pressure with consequent reduced cerebral perfusion pressure, hypoperfusion, oedema, and a metabolism-flow mismatch in the white matter.<sup>38</sup>

Clearly these individual features are all separately consistent with an NAHI and the more syndromic elements there are present, the more certain one is about a diagnosis of NAHI syndrome. Even with a 'full-house', the presumptive diagnosis remains a 'suspected NAHI'. As in other areas of medicine a syndrome is a collection of signs and symptoms, and the more complete the collection, the more certain the diagnosis.

Risk factors for NAHI include a young parent, unmarried parent, co-habiting, a past history of child or domestic abuse, drug or alcohol abuse, a history of mental ill-health, an infant born prematurely, recurrent medical consultations or admissions to hospital, and a past history of social work enquiry or involvement. The expectation therefore is that these abused children are frequently born prematurely, are of low birth weight, live with unmarried parent(s), in an abusive environment, and have had previous contact with medical and social workers. While these risk factors do not make the diagnosis of inflicted injury, they are supportive in much the same way as risk factors that are identified in children with a diagnosis of 'failure to thrive'. It must be recognised, however, that inflicted injury to children may occur in circumstances without easily identifiable risk factors and NAHI knows no racial, social class, or ethnic boundaries, and even disabled children are not exempt.<sup>39</sup>

A very contentious scenario is where children present with subdural and retinal haemorrhages only, with no history of trauma or a history of minor trauma only, e.g. from a short fall (less than three feet). In such circumstances and after thorough investigation, the clinician can only state that these injuries are consistent with an injury of non-accidental origin.

The clinician's approach to making a diagnosis of NAHI begins with taking a history of any trauma (no history of trauma is not the same as a history of no trauma). Second, it will be quite evident if there are signs of 'malicious injury' which clarifies the diagnosis. Third, after extensive investigation to exclude alternative diagnoses, the clinician should determine whether the injuries are of the contact type (skull bruising, subgaleal haemorrhage or fracture, extradural haematoma, focal subdural), inertial injury type (SDH, retinal haemorrhage, traumatic axonal injury, encephalopathy), or a combination of contact and inertial injury. Based on the above, the clinician is then

reasonably able to conclude that the brain injury is:

- definitely due to a non-accidental cause;
- consistent with a non-accidental cause;
- possibly due to a non-accidental cause;
- or not a result of non-accidental trauma.

Few prospective studies have been carried out in this complex condition, which would allow more certainty in reaching a diagnosis. Goldstein, in one prospective study, predicted that a combination of any two of the following three factors was consistent with inflicted head injury ( $p < 0.001$ ):

- 1 inconsistent history/physical examination;
- 2 retinal haemorrhages; and
- 3 parental risk factors (alcohol or drug abuse, previous social service intervention within the family, or a past history of child abuse or neglect).<sup>40</sup>

Although a number of clinical features are consistent with NAHI, it is my opinion that there is no single clinical or ophthalmological finding that is pathognomonic for NAHI. Although perimacular retinal folds were previously regarded as virtually diagnostic of abusive head trauma from shaking, in a recent case report Lantz describes these ocular findings in a 14-month-old child who was fatally injured as a result of the television set toppling onto him.<sup>41</sup>

Donahoe reviewed 54 articles or abstracts between 1966 and 1988 and reported that there was inadequate scientific evidence to make firm conclusions on most aspects of causation, diagnosis, treatment or any other matters pertaining to SBS.<sup>42</sup> Many other syndromic diagnoses would probably be found wanting if subjected to a critical appraisal of the literature when assessing the evidence base. Also although he reported inadequate evidence on the treatment aspects of this condition, it is unlikely that the treatment would be different or contentious in most centres, and its lack of evidence base does not criticise the treatment, neither does it therefore negate the entity. As the author points out, SBS urgently needs a properly controlled prospective trial using a variety of controls.

## CAN ACCIDENTAL INJURIES OR OTHER NON-TRAUMATIC CONDITIONS SIMULATE NAHI?

Numerous congenital or acquired pathologies may be associated with, or predispose to, individual components of the SBS. If we consider first an isolated SDH or hygroma this may be due to infections (septicaemia, meningitis, and necrotising encephalitis), inborn and other rare metabolic errors, (such as glutaric aciduria Type I, Menkes disease), thrombophilic disorders (vitamin K deficiency, IDP, malignancies including leukaemia, brain tumours, haemophilia, factor V deficiency, defibrination



with infection), low intracranial pressure syndromes (such as slit ventricle syndrome, hyperosmolar dehydration resulting from mannitol), and other types of trauma, such as birth and accidental trauma, in particular 'short fall' injuries. While thorough investigation will exclude many of the above rare or obvious conditions, one source of recent controversy concerns the infant suffering a short fall.

Short falls are often cited as an explanation or as a defence in SBS cases. They are regularly reported as falls from a bed, changing table or the parent's arms. We have seen babies of five weeks' of age arch backwards, effectively diving from a parent's shoulder and single-handed hold, falling 5 feet onto a tiled floor. The focal bruising, extensive skull fractures, and focal brain contusion, is not accompanied by a concussive element or other encephalopathy or delay in seeking treatment. Simple investigation of the circumstances therefore determines that such impact deceleration injuries are explicable.

Toddlers fall very frequently out of harnesses and baby bouncers, and undoubtedly fatal and serious injury can occur from low height falls, but these are exceptionally rare. Baby-walker injuries, with falls down stairs are potentially very serious, and falls from top bunks may also rarely produce SDHs. When an SDH is present this indicates a rotational injury, and a critical rotational velocity must have been attained for concussion, and for subdural to have occurred from very short falls. A 'short impact time' and a 'high terminal velocity' would be unusual with these minor falls, but with injuries that result during a fall when the head strikes an object causing acceleration rapidly in one direction followed immediately by rotation in the opposite direction, then sufficient rotational accelerations may be attained to induce haemorrhage.

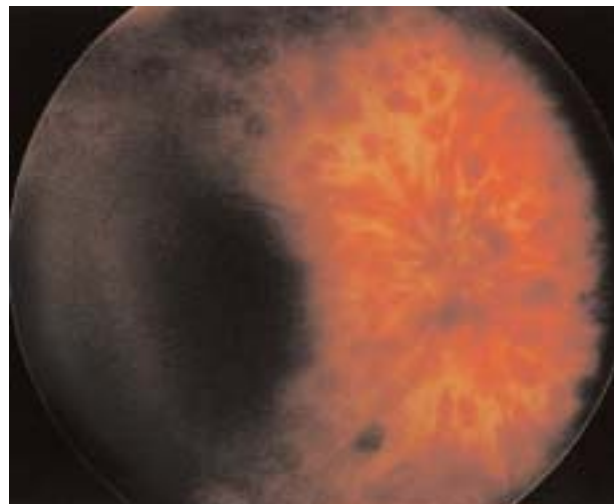
One study found 18 recorded head injury fatalities in children from 12 months to 13 years who had independently witnessed impact-deceleration injuries during falls from play ground equipment. Some of these children had bilateral retinal haemorrhages, however, none were suspected to have a non-accidental origin and all these children were aged outwith infancy when shaking injury occurs.<sup>43</sup>

Retinal haemorrhages may also be due to other causes such as meningococcal meningitis. Superficial flame or splinter shaped retinal haemorrhages may follow normal birth but resolve usually within three weeks while deeper layer retinal haemorrhages (dot or blot shaped) resolve generally within two to four weeks. Elevated intracranial pressure, coagulopathies, anaemia and hypo- or hypertension, vitamin K or C deficiency, anoxia, meningitis, and drowning are rarely complicated by retinal haemorrhages and when they do occur they are few and

confined to the posterior pole of the retina. Retinal haemorrhages in accidental head injury are rare, but they may occur particularly after high velocity side-impact road traffic accidents. The retinal haemorrhages of shaking or NAHI are, by contrast, severe and extensive throughout the retina and involve the sub-retinal, intra-retinal, and pre-retinal layers and extend to the ora serrata (Figure 3). The bleeding may advance to the vitreous or may cause retinal detachment. The most favoured explanation for the retinal haemorrhages in shaking injury is that of vitreous traction. The vitreous is attached to the retina at its periphery and, at different inertias, this is the site where shearing forces will tear the vitreous attachments from the retina or ora serrata and cause disruption of ocular and orbital blood vessel integrity. The mechanism is therefore similar to the shearing forces that cause subdural bleeds and cortical tears.

Diseases with skeletal lesions that simulate abuse are potentially many, and some are associated with fracture, some with irregular metaphyses and some with osteopenia. Most such conditions would not be readily confused with accidental or non-accidental causes but where typical radiological features are suggestive of non-accidental injury these differential diagnoses must be considered, e.g. rickets of prematurity, leukaemia, drug induced bone changes, inherited bone dysplasias, Sickle cell disease, scurvy, congenital indifference or insensitivity to pain, infantile cortical hyperostosis, copper deficiency, congenital cytomegalo virus, and osteogenesis imperfecta types I and IV.

Retinal haemorrhages, SDHs, and multiple fractures, individually may be due to many causes but when in combination (i.e. SDH with cerebral oedema, fractured ribs, and retinal haemorrhage), they become a reliable pointer to a non-accidental injury. Few differential diagnoses include these combinations, and birth and accidental trauma are the important aetiologies to exclude.



**FIGURE 3** Multiple multi-layer retinal haemorrhages, extending to the ora serrata, typical of non-accidental 'shaking' injury.

## Outcome

Non-accidental head injury affects approximately 25 infants per 100,000 each year<sup>44</sup> and given the number of children on at-risk registers from all forms of child abuse, NAHI represents a very small (less than 0.5%) proportion of all cases of child abuse. Although numerically small, NAHI is responsible for most of the physical handicap following child abuse, with the brain damage causing permanent disability from learning difficulties, motor disability, blindness, epilepsy, and organic behaviour problem. In one large Canadian study of 364 children, 19% died from their injuries, and of the survivors, 50% had ongoing neurological injury, and 65% had visual

impairment. Our own experience is that less than 10% have no developmental impairment. The pain and suffering from beating, bruising, and fractures is often compounded by the fear of a child being abused by a parent, guardian or friend from whom the expectation is of love and protection. In addition, many children have a resultant life sentence of permanent emotional damage causing themselves to be future abusers incapable of forming stable, trusting and loving relationships. In summary, adults do seriously injure infants' brains by shaking as well as other mechanisms, but in each individual case all the circumstances, and possible alternative explanations must be investigated before provisionally diagnosing NAHI.

## REFERENCES

- Caffey J. Multiple fractures in the long bones of infants suffering from chronic subdural hematoma. *Am J Roentgenol* 1946; **56(2)**:163–73.
- Ommaya AK, Faas F, Yarnell P. Whiplash injury and brain damage: an experimental study. *JAMA* 1968; **204(4)**:285–9.
- Ommaya AK, Gennarelli TA. Cerebral concussion and traumatic unconsciousness. Correlation of experimental and clinical observations of blunt head injuries. *Brain* 1974; **97(4)**:633–54.
- Ommaya AK, Yarnell P. Subdural haematoma after whiplash injury. *Lancet* 1969; **2(7614)**:237–9.
- Guthkelch AN. Infantile subdural haematoma and its relationship to whiplash injuries. *Br Med J* 1971; **2(759)**:430–1.
- Caffey J. On the theory and practice of shaking infants. Its potential residual effects of permanent brain damage and mental retardation. *Am J Dis Child* 1972; **124(2)**:161–9.
- Duhaime AC, Gennarelli TA, Thibault LE, Bruce DA, Margulies SS, Wiser R. The shaken baby syndrome. A clinical, pathological, and biomechanical study. *J Neurosurg* 1987; **66(3)**:409–15.
- King WJ, MacKay M, Sirnack A; Canadian Shaken Baby Study Group. Shaken baby syndrome in Canada: clinical characteristics and outcomes of hospital cases. *CMAJ* 2003; **168(2)**:155–9.
- Minns RA, Millar C, Minns FC, Lo TYM, Jones PA, Barlow KM. Non-accidental head injury in Scotland: Scottish database. In: Minns RA, Brown JK (editors). *Shaken baby syndrome and other non-accidental head injuries*. Edinburgh: Mackeith Press; 2004.
- Reece RM, Nicholson CE. *Inflicted childhood neurotrauma. Proceedings of a conference sponsored by HHS, NIH, NICHD, ORD, NCMRR*. Reece RM, Nicholson CE (editors). 02 Oct 10; American Academy of Pediatrics, 2003.
- Pounder DJ. Shaken adult syndrome. *Am J Forensic Med Pathol* 1997; **18(4)**:321–4.
- Carrigan TD, Walker E, Barnes S. Domestic violence: the shaken adult syndrome. *J Accid Emerg Med* 2000; **17(2)**:138–9.
- Gennarelli TA, Thibault LE. Biomechanics of acute subdural hematoma. *J Trauma* 1982; **22(8)**:680–6.
- Hodgson DC, Shippen JM, Sunderland R. Protective role of cerebrospinal fluid in brain injuries. *Arch Dis Child* 2001; **84(2)**:187.
- Ommaya AK, Fisch FJ, Mahone RM, Corrao P, Letcher F. Comparative tolerances for cerebral concussion by head impact and whiplash injury in primates. In: Backaitis SH (editor). *Biomechanics of Impact Injury and Injury Tolerances of the Head Neck Complex*. Warrendale, PA: Society of Automotive Engineers; 1993: 265–74.
- Prange MT, Margulies SS. Regional, directional, and age-dependent properties of the brain undergoing large deformation. *J Biomech Eng* 2002; **124(2)**:244–52.
- Thibault KL, Margulies SS. Age-dependent material properties of the porcine cerebrum: effect on pediatric inertial head injury criteria. *J Biomech* 1998; **31(12)**:1119–26.
- Raghupathi R, Margulies SS. Traumatic axonal injury after closed head injury in the neonatal pig. *J Neurotrauma* 2002; **19(7)**:843–53.
- Zhou C, Khalil TB, King AI. *Viscoelastic response of the human brain to sagittal and lateral rotational acceleration by finite element analysis*. International IRCOBI Conference on the Biomechanics of Impacts. 1996.
- Abel JM, Gennarelli TA, Segawa H. *Incidence and severity of cerebral concussion in the rhesus monkey following sagittal plane angular acceleration*. Proceedings 22nd Stapp Car Crash Conference. Warrendale, PA: Society of Automotive Engineers, 1978.
- Morison CN. *The dynamics of shaken baby syndrome*. Birmingham University, UK, PhD Thesis 2002.
- Holbourne AHS. Mechanics of head injury. *Lancet* 1943; **2**:438–41.
- May PR, Fuster JM, Haber J, Hirschman A. Woodpecker drilling behavior: An endorsement of the rotational theory of impact brain injury. *Arch Neurol* 1979; **36(6)**:370–3.
- Jones PA, Andrews PJ, Easton VJ, Minns RA. Traumatic brain injury in childhood: intensive care time series data and outcome. *Br J Neurosurg* 2003; **17(1)**:29–39.
- Minns RA, Lawson G, Millar C, Cleugh FM, McBride K, Brash H et al. Biomechanical studies of volunteers and doll models during shaking simulation. In press.
- de San Lazaro C, Harvey R, Ogen A. Shaking infant trauma induced by misuse of a baby chair. *Arch Dis Child* 2003; **88(7)**:632–4.
- Alexander RC, Schor DP, Smith WL, Jr. Magnetic resonance imaging of intracranial injuries from child abuse. *J Pediatr* 1986; **109(6)**:975–9.
- Cohen RA, Kaufman RA, Myers PA, Towbin RB. Cranial computed tomography in the abused child with head injury. *AJR Am J Roentgenol* 1986; **146(1)**:97–102.
- Janpan T, Narborough G, Punt JA, Lowe J. Cerebral contusional tears as a marker of child abuse – detection by cranial sonography. *Pediatr Radiol* 1992; **22(4)**:237–45.
- Sato Y, Yuh WT, Smith WL, Alexander RC, Kao SC, Ellerbroek CJ. Head injury in child abuse: evaluation with MR imaging. *Radiology* 1989; **173(3)**:653–7.
- Zimmerman RA, Bilaniuk LT, Genneralli T. Computed tomography of shearing injuries of the cerebral white matter. *Radiology* 1978; **127(2)**:393–6.
- Barlow KM, Gibson RJ, McPhillips M, Minns RA. Magnetic resonance imaging in acute non-accidental head injury. *Acta Paediatr* 1999; **88(7)**:734–40.
- Lo TY, McPhillips M, Minns RA, Gibson RJ. Cerebral atrophy following shaken impact syndrome and other non-accidental head injury (NAHI). *Pediatr Rehabil* 2003; **6(1)**:47–55.
- Lindley DV. Statistical inference (with discussion). *J R Stat Soc* 1953; **15(Series B)**:30–76.
- Lazoritz S, Baldwin S, Kini N. The whiplash shaken infant

- syndrome: has Caffey's syndrome changed or have we changed his syndrome? *Child Abuse Negl* 1997; **21(10)**:1009–14.
- 36 Minns RA, Busuttill A. Patterns of presentation of the shaken baby syndrome. *BMJ* 2004; **328**:766.
- 37 Geddes JF, Hackshaw AK, Vowles GH, Nickols CD, Whitwell HL. Neuropathology of inflicted head injury in children. I. Patterns of brain damage. *Brain* 2001; **124(7)**:1290–8.
- 38 Shaver EG, Duhaime AC, Curtis M, Gennarelli LM, Barrett R. Experimental acute subdural hematoma in infant piglets. *Pediatr Neurosurg* 1996; **25(3)**:123–9.
- 39 MacKeith R. Speculations of non-accidental injury as a cause of chronic brain disorder. *Dev Med Child Neurol* 1974; **16(2)**:216–18.
- 40 Goldstein B, Kelly MM, Bruton D, Cox C. Inflicted versus accidental head injury in critically injured children. *Crit Care Med* 1993; **21(9)**:1328–32.
- 41 Lantz PE, Sinal SH, Stanton CA, Weaver RG Jr. Perimacular retinal folds from childhood head trauma. *BMJ* 2004; **328(7442)**:754–6.
- 42 Donohoe M. Evidence-based medicine and shaken baby syndrome: part I: literature review, 1966–1998. *Am J Forensic Med Pathol* 2003; **24(3)**:239–42.
- 43 Plunkett J. Fatal pediatric head injuries caused by short-distance falls. *Am J Forensic Med Pathol* 2001; **22(1)**:1–12.
- 44 Barlow KM, Minns RA. Annual incidence of shaken impact syndrome in young children. *Lancet* 2000; **356(9241)**:1571–2.

## ROYAL COLLEGE OF PHYSICIANS OF EDINBURGH

### Forthcoming Symposia for 2005



All symposia are held at the Royal College of Physicians of Edinburgh unless otherwise stated. Further symposia may be added at a later date.

- |   |                |
|---|----------------|
| • Aberdeen Symposium:<br><b>Updates in acute medicine</b>   | 16 March       |
| • <b>Respiratory medicine</b>   | 18 March       |
| • <b>Rheumatology</b>   | 3 May          |
| • <b>Therapeutics</b>   | 13 May         |
| • <b>Maternal medicine</b>  | 26 May         |
| • <b>Clinical Genetics</b>  | 9 September    |
| • RCPE/RCPCH Joint Symposium:<br><b>Obesity in childhood and adolescence: epidemiology, management and mechanisms</b>   | 15 September   |
| • <b>Expedition Medicine</b>  | 30 September   |
| • <b>Medical Education</b>  | 14 October     |
| • Joint meeting between RCSE, RCPE, British Society for Gastroenterology and the Association of Colo-Proctology of Great Britain and Northern Ireland to celebrate the Quincentenary of the Royal College of Surgeons of Edinburgh<br><b>Inflammatory bowel disease</b> | 17/18 November |